

Figure 2

Antiulcer activity study in the rat. Results of histological examination
Microscopic observation of gastric mucosa

Groups receiving *Globularia alypum* L. aqueous extract + indomethacin suspension

Photo 1: gastric mucosa with normal fundus (HE x 230)

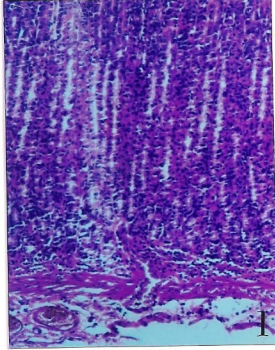
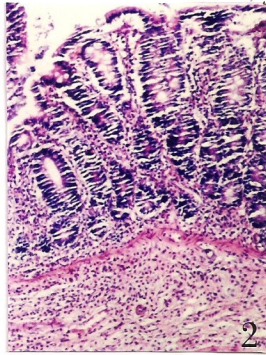


Photo 2: gastric mucosa with normal antrum (HE x 230)



Group receiving only indomethacin suspension

Photo 3: presence of mucosal ulcers constituted by an exudation of fibrin and leukocytes
(HE x 230)

